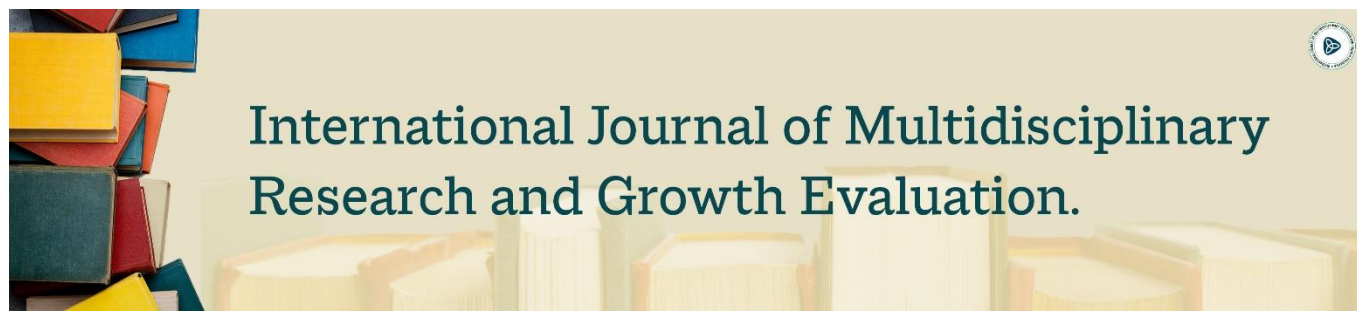



# International Journal of Multidisciplinary Research and Growth Evaluation.

## Evaluation of Hepatoprotective activity of *Cuscuta Reflexa*

Dr. Papagatla Poli Reddy <sup>1\*</sup>, Vuppu Satya <sup>2</sup>, Dr. KNV Rao <sup>3</sup>

<sup>1-3</sup> Department of Pharmacology, Nalanda College of Pharmacy, Charlapally, Nalgonda, Telangana, India

\* Corresponding Author: Dr. Papagatla Poli Reddy

### Article Info

ISSN (online): 2582-7138

Volume: 04

Issue: 04

July-August 2023

Received: 17-05-2023

Accepted: 07-06-2023

Page No: 129-134

### Abstract

*Cuscuta Reflexa* from Convolvulaceae family is a plant with a variety of ethnic medicinal uses along with antioxidant activity. Hence it was planned to evaluate the hepatoprotective activity with methanolic extracts of whole plant of *Cuscuta Reflexa* (MECR) and aqueous extracts of whole plant of *Cuscuta Reflexa* (AQECR). Hepatoprotective activity of both the extracts was studied against galactosamine induced hepatotoxicity in rats. Biochemical parameters Alanine aminotransferase (ALT), Aspartate aminotransferase (AST), Serum alkaline phosphatase (ALP), Serum direct bilirubin (BILD), Serum total bilirubin (BILT), Serum albumin (ALB), Serum total proteins (PRO), Serum cholesterol (CHO), and histopathological changes of livers were assessed in control/toxicant/standard/and extract treated animals with galactosamine induced hepatotoxic models in rats. In LD<sub>50</sub> studies for MECR and AQECR up to the maximum dose level of 2000 mg/kg dose no mortality was observed in any of the animals, indicating the practically nontoxic. When compared to toxicant control groups both the extracts have significantly reduced the paracetamol induced elevated levels of serum ALT, AST, ALP, BILT, BILD, CHO, and elevated the levels of ALB and PRO. The histopathological changes (steatosis), necrosis etc. Were partly or fully prevented in animals treated with the two extracts. MECR and AQECR showed a significant hepatoprotective effect against galactosamine induced hepatic damage. The medium and high doses of AECR and AQECR (200 and 400 mg/kg) treated groups showed better hepatoprotective activity when compared to standard drug silymarin (25 mg/kg). Studies for MECR and AQECR up to the maximum dose level of 2000 mg/kg dose no mortality was observed in any of the animals, indicating the practically nontoxic. When compared to toxicant control groups both the extracts have significantly reduced the paracetamol induced elevated levels of serum ALT, AST, ALP, BILT, BILD, CHO, and elevated the levels of ALB and PRO. The histopathological changes (steatosis), necrosis etc. Were partly or fully prevented in animals treated with the two extracts.

DOI: <https://doi.org/10.54660/IJMRGE.2023.4.4.129-134>

**Keywords:** *Cuscuta Reflexa*, Paracetamol, Silymarin, Hepatoprotective activity

### Introduction

Hepatotoxicity may result from direct toxicity of the primary compound and/or from a reactive metabolite or from an immunologically-mediated response affecting hepatocytes, biliary epithelial cells and/or liver vasculature <sup>[1]</sup>. Hepatotoxicants are exogenous compounds of clinical relevance and may include overdoses of certain medicinal drugs, industrial chemicals and natural chemicals like microcystins, herbal remedies and dietary supplements <sup>[2]</sup>. Certain drugs may cause liver injury when introduced even within the therapeutic ranges. The hepatotoxic response elicited by a chemical agent depends on the concentration of the toxicant which may be either parent compound or toxic metabolite, differential expression of enzymes and concentration gradient of cofactors in blood across the acinus <sup>[3]</sup>. Hepatotoxic response is expressed in the form of characteristic patterns of cytolethality in specific zones of the acinus. Hepatotoxicity related symptoms may include a jaundice or icterus appearance causing yellowing of the skin, eyes and mucous membranes due to high level of bilirubin in the extracellular fluid, pruritus, severe abdominal pain, nausea or vomiting, weakness, severe fatigue, continuous bleeding, skin rashes, generalized itching, swelling of the feet and/or legs, abnormal and rapid weight gain in a short period of time, dark urine and light colored stool <sup>[4]</sup>.

*Cuscuta Reflexa* Roxb is a rootless, leafless perennial parasitic twining herb of Convolvulaceae family, commonly known as Akashvalli or Dodder. The plant is distributed worldwide and in India about 6 species are found. It has no chlorophyll and cannot make its own food by photosynthesis. It grows on thorny or other shrubs, sometimes completely covering the bushes and trees [5]. It spread from one host to another, and on each victim, they twine and cling tightly with special branching organs called haustorium. Haustorium penetrate the host and connect to the host xylem as well as to the host phloem and absorb from it both water and elaborated food stuffs such as sugar and amino acid. The connection (haustorium) at the contact site is established through the secretion of enzymes and sticky substances consisting mainly of de-esterified pectins [6]. The *Cuscuta Reflexa* is investigated for antitumor, antimicrobial [7], hepatoprotective [8], anticonvulsant [9], antioxidant [10], induced alopecia [11] activities. Many chemical constituents have been isolated from *Cuscuta Reflexa* such as cuscutin, amarbelin, beta-sterol, stigmaterol, myricetin, quercetin, cuscutamine, luteolin, bergenin etc. [12] The present investigation is designed in order to study the *in vivo* hepatoprotective activity methanol and water extract of whole part of the plant *Cuscuta Reflexa* Roxb. (Convolvulaceae). Galactosamine induced hepatotoxic rat models were chosen to examine the hepatoprotective activity of *Cuscuta Reflexa* (CR) and compared with silymarin (SL) as reference standard. The whole plant extracts of CR was also subjected to preliminary phytochemical screening after each successive extraction.

## Materials and Methods

**Plant Materials and Chemicals:** Whole part of the plant *Cuscuta Reflexa* (CR) were collected from different parts of Ranga Reddy District, Telangana, India and authenticated by Dr. Madhava Chetty, Assistant Professor, Sri Venkateswar University, Tirupati, Andhra Pradesh, India. Glucosamine, obtained as a gift sample from Alax Bioresearch, Ahmedabad, Gujarat, India. Silymarin (SL), SGOT (Serum Glutamate Oxaloacetate Transaminase) Kit, SGPT (Serum Glutamate Pyruvate Transaminase) Kit and ALP (Alkaline Phosphatase) Kits were purchased from Scientific Corporation, Rasulgarh, Bhubaneswar, Odisha. Petroleum ether, chloroform, methanol, carbon tetrachloride and ethanol were purchased from Merck. All the reagents used were of analytical grade and were used as received.

**Animals:** Albino rats of Wistar strain weighing 100-150 g of either sex were purchased from M/s Ghosh Enterprises, Kolkata and used for the study. The animals were housed individually in polypropylene cages at a temperature of  $27 \pm 2^\circ\text{C}$  and 50 – 60 % RH with food and an unlimited supply of drinking water. Animals were kept on a standard light / dark cycle (12 hr/12 hr) with lights on at 7:00 AM. The animals were randomly selected, marked to permit individual identification, and kept in their cages for 7 days prior to dosing to allow for acclimatisation to the laboratory conditions. They were fed with Amrut Laboratory Animal Feed (Nay Maharashtra Chakan Oil Mills Ltd, Pune).

## Extraction of plant materials

The plant material which was powdered and stored was used for extraction. A weighed quantity of each of the plant powdered material was extracted by cold maceration with 50% methanol for 72 hrs with intermediate heating at  $40^\circ\text{C}$  one time in a day. After that the residues was extracted with

water for aqueous extract. The extract was filtered using Whatmann filter paper and then the filtrate was concentrated under reduced pressure and controlled temperature ( $40-50^\circ\text{C}$ ). The marc was dried and weighted. This marc was again extracted with water by cold maceration for 72 hrs to yield aqueous extracts.

## Preliminary phytochemical screening

The whole plant part extracts of CR obtained after each successive steps were subjected to qualitative chemical testing for preliminary screening of phytoconstituents. Phytochemical screening were performed using standard procedures [13, 14]. Phytochemical screening of CR extracts include test for alkaloids, saponins, glycosides and sugar, phenolic compounds and tannins, flavonoids and flavones, coumarin and its derivatives and triterpenoids.

## In Vivo Hepatoprotective Studies

### Acute toxicity studies

Acute oral toxicity [15] study was performed as per OECD-423 guidelines (acute toxic class method). *Wistar* rats (n = 3) of either sex selected by random sampling technique were used for the study. The animals were kept fasting for a overnight providing only water, after which the extracts were administered orally at the dose level of 5 mg / kg body weight by intragastric tube and observed for 14 days. If mortality was observed in 2-3 animals, then the dose administered was assigned as toxic dose. If mortality was observed in 1 animal, then the same dose was repeated again to confirm the toxic dose. If mortality was not observed, the procedure was repeated for further higher doses such as 50, 300 and 2000 mg / kg body weight.

### Preparation of the drug for the experimental study

The extracts and the standard drugs were administered in the form of suspension in water with 1% sodium carboxymethyl cellulose as suspending agent.

### Preparation of the standard

Silymarin, a known hepatoprotective agent was used as the reference for comparison at a dose of 25 mg/kg body weight in 0.3% CMC.

### Experimental design

Animals were divided into 11 groups comprising of 6 animals in each group. Each group received the following treatment.

Group I: Normal control (0.3% CMC).

Group II: Hepatotoxicant (d-galactosamine 600 mg/kg) by i.p route as single dose

Group III: Aqueous extract of *Cuscuta Reflexa* at a dose of 200 mg/kg body weight.

Group IV: Aqueous extract of *Cuscuta Reflexa* at a dose of 400 mg/kg body weight.

Group V: 50% methanol extract of *Cuscuta Reflexa* at a dose of 200 mg/kg body weight.

Group VI: 50% methanol extract of *Cuscuta Reflexa* at a dose of 400 mg/kg body weight.

Group VII: Silymarin positive control

All these treatments were given orally for 14 days. On the 14th day, after 1h of sample administration, except normal control animals (G-1) all the animal in groups (G-2 to G-11) received single dose of 600 mg/kg intraperitoneal injection of d-galactosamine dissolved in saline. After 48 hours d-galactosamine administration all the animals were sacrificed

by cervical decapitation under light ether anaesthesia. The liver and blood were collected from all these animals on the same day for biochemical (SGOT<sup>[16]</sup>, SGPT<sup>[16]</sup>, ALP<sup>[17]</sup>, total protein<sup>[18]</sup> and total bilirubin<sup>[19]</sup>) and histopathological estimations.

### Histopathological study of liver

Immediately after sacrificing the rats, small pieces of liver tissues were fixed in 10% formalin and proceed for embedding in paraffin sections. Serial sections of 5  $\mu$ m thickness were made, stained with hematoxyline and eosin followed by examination under microscope for histopathological changes.

### Statistical Analysis

Statistical analysis was carried out using GraphPad software (GraphPad InStat) by one-way Analysis of Variance (ANOVA) followed by Dunnett's test. Results are expressed as mean  $\pm$  SEM from six rats in each group. P values < 0.05 were considered significant.

### Result and Discussion

In the qualitative phytochemical analysis of *Cuscuta Reflexa*, 50% methanol extract and aqueous extract showed the presence of alkaloids, terpenoid, tannins, flavanoid, phenol, carbohydrates, glycoside and mucilage.

The ethanol, 50% methanol, and aqueous extracts of *Cuscuta Reflexa* were evaluated for its hepatoprotective activity against d-galactosamine induced hepatic damage. Healthy adult male albino rats of *Wistar* strain weighing 180-220 g were used for the study. Silymarin was used as positive control. The plant extracts at two different dose levels (200, 400 mg/kg, po), showed significant hepatoprotective activity as evidenced by an alteration in the serum enzyme levels.

The effect of *Cuscuta Reflexa* at both the dose levels on marker enzymes in serum against d-galactosamine induced hepatotoxicity was shown in Table-18. Liver damage induced by dgalactosamine significantly increased the marker enzymes like AST, ALT and ALP in serum (P<0.05). Oral administration of the plant extracts of *Cuscuta Reflexa* significantly decreased the level of marker enzymes AST, ALT and ALP (P<0.01) in serum. The total bilirubin level was significantly increased (P<0.05) in d-galactosamine treated animals. The plant extracts treated animals showed a significantly lower bilirubin level in serum. The total protein

level in serum was considerably reduced in d-galactosamine toxicity. The plant extracts treated animals significantly increased (P<0.05) the total protein level in serum (Fig.1).

In the assessment of liver damage by d-galactosamine, the determination of enzyme levels is largely used. The changes observed with viral hepatitis are also seen in d-galactosamine administration<sup>[20]</sup>.

Hence d-galactosamine induced liver toxicity was chosen as the experimental model. The ability of the liver protective drugs to reduce the injurious effects or to preserve the normal hepatic physiological mechanisms, which had been disturbed by the hepatotoxin, is the index of its protective effect<sup>[21]</sup>. The enzymes like AST and ALT are cytoplasmic in origin and necrosis or membrane damage releases the enzymes into circulation and therefore can be measured in the serum<sup>[22]</sup>. Elevated levels of serum enzymes are indicative of cellular leakage and loss of functional integrity of cell membrane in liver<sup>[23]</sup>. In addition, destruction of hepatic cells causes an elevation in the serum levels of acid phosphatase (ACP) and bilirubin. ACP is localized almost exclusively in the particles and its release parallels that of lysosomal hydrolases. Increase in the serum level of ALP is due to increased synthesis, in the presence of increasing biliary pressure.

The present study revealed a significant increase in the marker enzymes like AST, ALT, ALP and serum bilirubin levels, on exposure to dgalactosamine, indicating considerable hepatocellular injury. Oral administration of *Cuscuta Reflexa* at two different dose levels attenuated the increased levels of the marker enzymes produced by d-galactosamine and caused a subsequent recovery towards normalization almost like that of standard silymarin treatment. The decreased total protein level observed in the rats treated with dgalactosamine may be due to the decrease in the number of hepatocytes which in turn may result in decreased hepatic capacity to synthesis protein<sup>[24]</sup>. On administration of extracts *Cuscuta Reflexa* showed significant increase in total protein level, which indicates the increase in hepatocyte levels, accounting for its hepatoprotective effect. The subsequent recovery towards normalization of these enzymes strongly suggest the possibility of the extracts being capable of conditioning the hepatocytes so as to cause accelerated regeneration of parenchymal cells. The results showed that the extracts of the plant drugs *Cuscuta Reflexa* at different dose levels offer hepatoprotection (Table 1).

**Table 1:** Effect of the extracts on serum biochemical parameters on control and experimental animals

Group	Treatment	AST(U/L)	ALT(U/L)	ALP(U/L)	TP(mg/dL)	TB(mg/dL)
1	Normal control (1% SMC 10ml/ kg)	46.11 $\pm$ 0.86	32.5 $\pm$ 2.39	125.39 $\pm$ 19.15	7.45 $\pm$ 0.15	0.48 $\pm$ 0.01
2	Hepatotoxicant dgalactosamine (600 mg/kg)	99.31 $\pm$ 8.62 <sup>a</sup>	80.84 $\pm$ 3.62 <sup>a</sup>	237.79 $\pm$ 12.65 <sup>a</sup>	0.97 $\pm$ 0.24 <sup>a</sup>	2.84 $\pm$ 0.12 <sup>a</sup>
3	Aqueous extract of <i>Cuscuta Reflexa</i> (200 mg/kg)	68.53 $\pm$ 2.80 <sup>b</sup>	63.80 $\pm$ 2.30 <sup>d</sup>	185.54 $\pm$ 15.63 <sup>d</sup>	5.85 $\pm$ 1.25 <sup>c</sup>	2.03 $\pm$ 0.02 <sup>b</sup>
4	Aqueous extract of <i>Cuscuta Reflexa</i> (400 mg/kg)	55.35 $\pm$ 2.56 <sup>b</sup>	57.31 $\pm$ 8.65 <sup>b</sup>	168.39 $\pm$ 10.96 <sup>b</sup>	6.11 $\pm$ 0.86 <sup>c</sup>	0.75 $\pm$ 0.01 <sup>b</sup>
5	50% methanol extract of <i>Cuscuta Reflexa</i> (200 mg/kg)	70.31 $\pm$ 1.36 <sup>b</sup>	66.59 $\pm$ 6.35 <sup>d</sup>	203.49 $\pm$ 9.86 <sup>d</sup>	4.63 $\pm$ 1.21 <sup>d</sup>	0.97 $\pm$ 0.02 <sup>b</sup>
6	50% methanol extract of <i>Cuscuta Reflexa</i> (400 mg/kg)	53.14 $\pm$ 3.86 <sup>b</sup>	58.29 $\pm$ 4.65 <sup>b</sup>	174.39 $\pm$ 9.42 <sup>c</sup>	5.84 $\pm$ 0.92 <sup>c</sup>	0.63 $\pm$ 0.02 <sup>b</sup>
7	Positive control (silymarin) (25 mg/kg)	50.44 $\pm$ 2.86 <sup>b</sup>	43.94 $\pm$ 2.38 <sup>b</sup>	150.55 $\pm$ 5.26 <sup>b</sup>	6.11 $\pm$ 0.82 <sup>c</sup>	0.53 $\pm$ 0.01 <sup>b</sup>

Values are expressed as mean  $\pm$  SEM; n = 6 in each group. aP <0.01 when compared to control; bP <0.01, cP<0.05 and dP>0.05 when compared to d-galactosamine control (one way ANOVA followed by Dunnett's test).

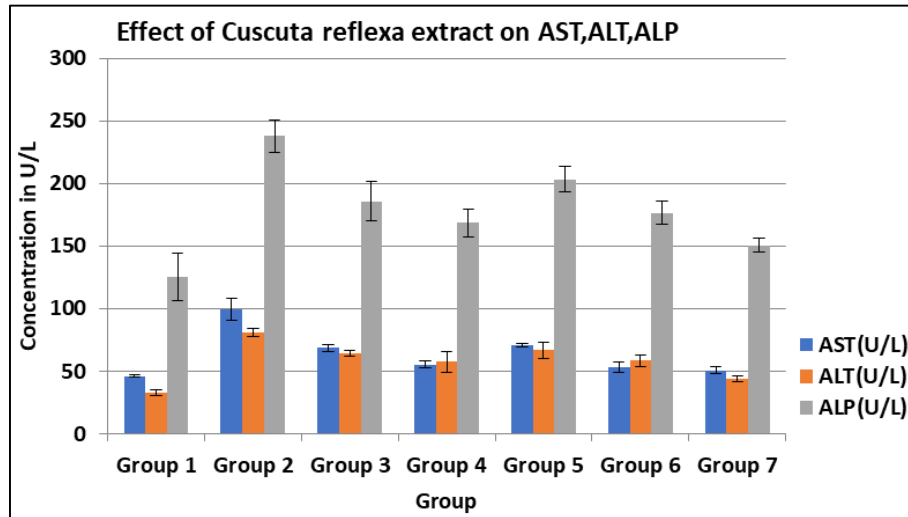


Fig 1

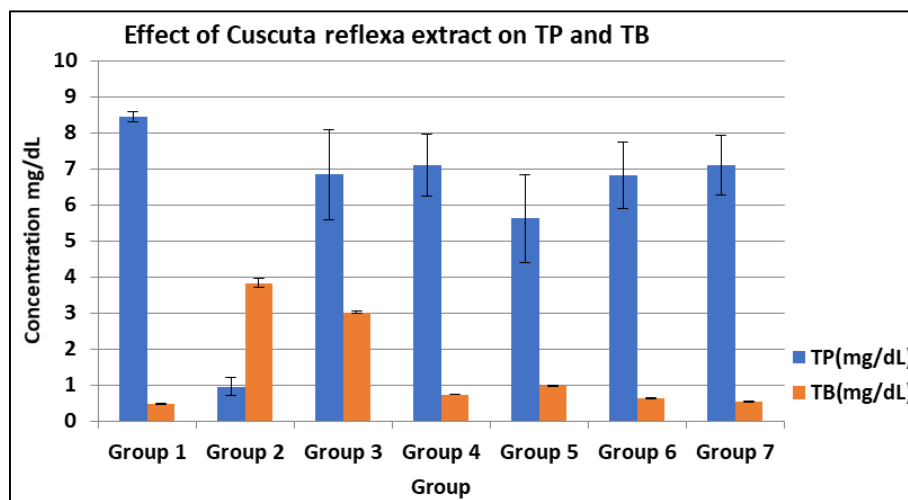


Fig 2

### Histopathological study

The histopathological profile of the rat liver of the normal control group showed normal liver with central vein and cords of hepatocytes. Liver of the rat treated with hepatotoxicant d-galactosamine showed severe hepatocellular degeneration with hepatocytes showing fatty changes. Hepatocytes showed early degenerative changes. The rat group treated with hepatotoxicant and aqueous extract of *Cuscuta Reflexa* at a dose level of 200 mg/kg body weight showed mild hepatocellular degeneration and that of the dose level 400 mg/kg body weight showed mild perilobular hepatocellular fatty changes.

The liver sections of the group treated with hepatotoxicant and 50% methanol extract of *Cuscuta Reflexa* at a lower dose of 200 mg/kg body weight showed dilated central vein and mild perilobular hepatocellular fatty changes and at a higher dose of 400 mg/kg body weight showed mild hepatocellular fatty changes.

Exogenous administration of d-galactosamine has been found to induce liver damage, which closely resembles human viral hepatitis [25].

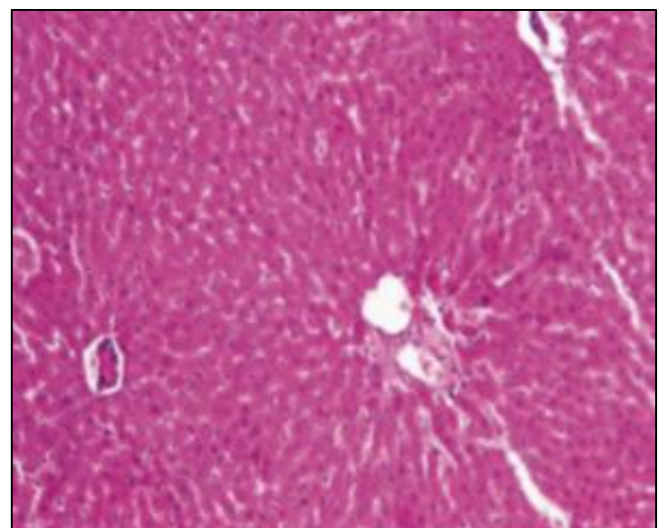
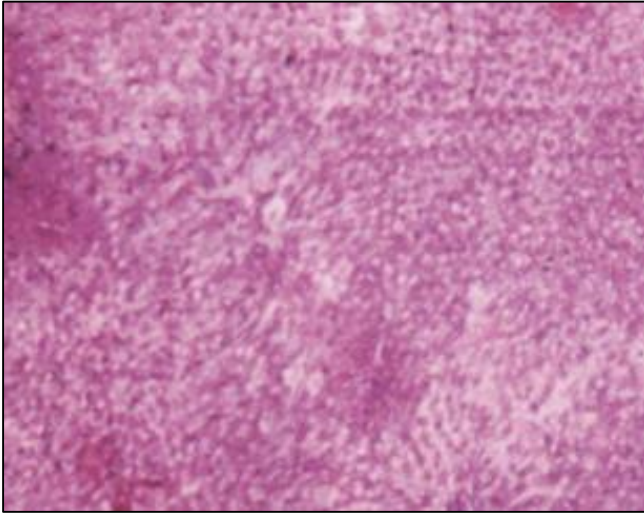
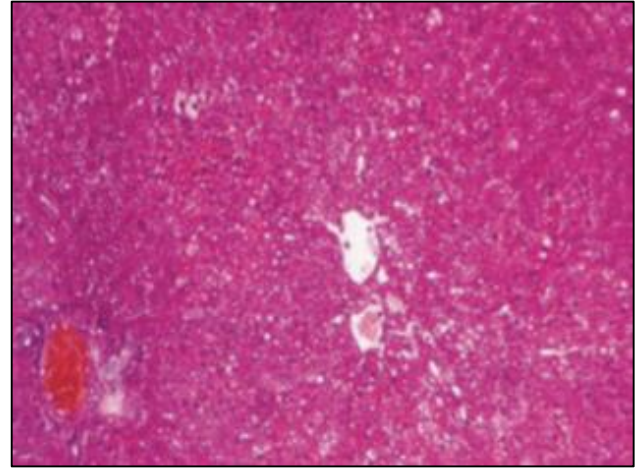


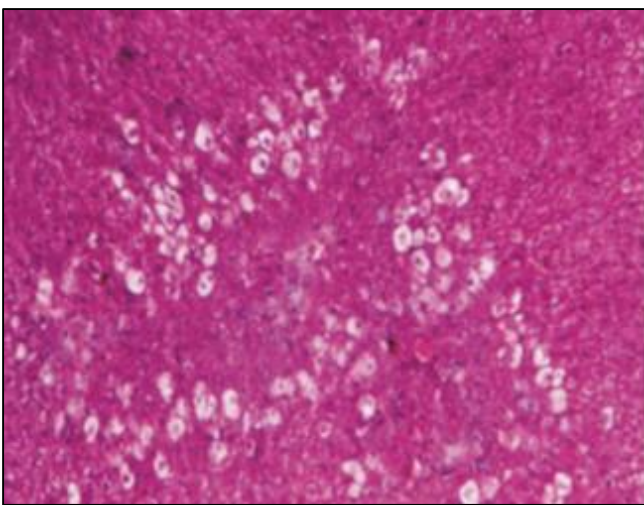
Fig 3: Rat (normal), showing normal liver with central vein and cords of hepatocytes. H & E  $\times 100$



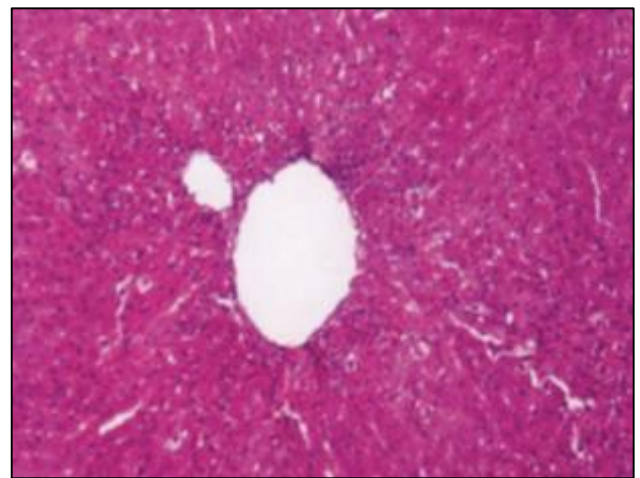
**Fig 4:** Rat (hepatotoxicant d-galactosamine), showing hepatocellular degeneration with fatty changes. H & E  $\times 100$



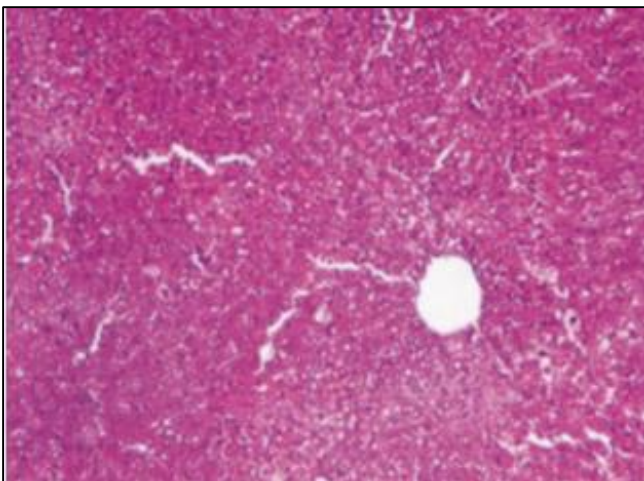
**Fig 7:** Rat treated with 50% methanol extract of *Cuscuta Reflexa* (200 mg/kg), showing dilated central vein with perilobular hepatocellular fatty changes. H & E  $\times 100$



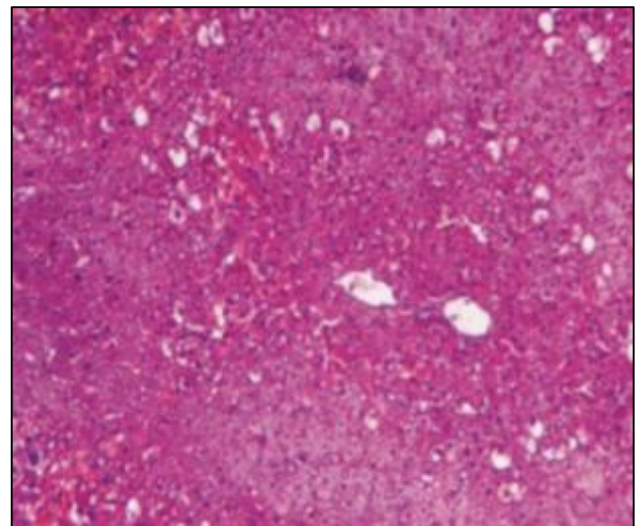
**Fig 5:** Rat treated with aqueous extract of *Cuscuta Reflexa* (200 mg/kg), showing mild hepatocellular degeneration. H & E  $\times 100$



**Fig 8:** Rat treated with 50% methanol extract of *Cuscuta Reflexa* (400 mg/kg), showing mild hepatocellular fatty changes. H & E  $\times 100$



**Fig 6:** Rat treated with aqueous extract of *Cuscuta Reflexa* (400 mg/kg), showing mild perilobular hepatocellular fatty changes



**Fig 9:** Rat (positive control) treated with Silymarin (25 mg/kg), showing normal central vein with mild hepatocytic fatty changes. H & E  $\times 100$

**Normal control:** Normal liver with central vein and cords of hepatocytes.

**D-Galactosamine (600mg/kg):** Hepatocellular degeneration with fatty changes.

**Aqueous extract of *Cuscuta Reflexa* (200 mg/kg):** Mild hepatocellular degeneration

**Aqueous extract of *Cuscuta Reflexa* (400 mg/kg):** Mild perilobular hepatocellular fatty changes.

**50% methanol extract of *Cuscuta Reflexa* (200 mg/kg):** Dilated central vein mild perilobular hepatocellular fatty changes.

**50% methanol extract of *Cuscuta Reflexa* (400 mg/kg):** Mild hepatocellular fatty changes.

### Conclusion

In present study d-galactosamine in larger dose produced liver necrosis. This may be due to depletion of several uracil nucleotides including UDP-glucose, UDP-galactose and UTP. This resulted in elevation in levels of quantitative markers in serum (i.e.) AST, ALT, ALP and total bilirubin [105]. Pretreatment with the extracts of the plants offered hepatoprotection as evidenced by an inhibition in the elevated AST, ALT, ALP and total bilirubin levels. The histopathological observations supported the evidence.

On the basis of results obtained in the present investigation, it can be concluded that the histopathological study of the liver of the extract treated rats showed normal structure which also confirms the hepatoprotective nature of the extracts. The hepatoprotective property of the extracts may be attributed to the presence of flavanoids, which are present in the plant. A large number of phenols and flavanoids are known to possess strong antioxidant and hepatoprotective properties [26-27].

### References

- Deng X, Luyendyk JP, Ganey PE, Roth RA. Inflammatory stress and idiosyncratic hepatotoxicity: Hints from animal models. *Pharmacological Reviews*. 2009;61(3):262-282.
- Papay JI, Clines D, Rafi R, Yuen N, Britt SD, *et al.* Drug-induced liver injury following positive drug rechallenge. *Regulatory Toxicology and Pharmacology*. 2009;54(1):84-90.
- Kedderis GL. Biochemical basis of hepatocellular injury. *Toxicologic Pathology*. 1996;24:77-83.
- Bleibel W, Kim S, D'Silva K, Lemmer ER. Drug-induced liver injury: Review article. *Digestive Diseases and Sciences*. 2007;52:2463-2471.
- Catterjee D, Sahu RK, Jha A, Dwivedi J. Evaluation of antitumor activity of *Cuscuta reflexa* Roxb (Cuscutaceae) against Ehrlich ascites carcinoma in Swiss albino mice. *Tropical Journal of Pharmaceutical Research*. 2011;10(4):448-453.
- Vaughn KC. Attachment of the parasitic weed dodder to the host. *Protoplasma*. 2002;219:227-237.
- Inamdar FB, Oswal RJ, Chorage TV, Garje K. *In vitro* antimicrobial activity of *Cuscuta reflexa* Roxb. *International Research Journal of Pharmacy*. 2011;2(4):214-216.
- Balakrishnam BR, Sangameswaran B, Bhaskar VH. Effect of methanol of *Cuscuta Reflexa* aerial parts on hepatotoxicity induced by antitubercular drugs in rats. *International Journal of Applied Research in Natural Products*. 2010;3(1):18-22.
- Borole SP, Oswal RJ, Antre RV, Kshirsagar SS, Bagul YR. Evaluation of anti-epileptic activity of *Cuscuta Reflexa* Roxb. *Research Journal of Pharmaceutical, Biological and Chemical Sciences*. 2011;2:657-663.
- Sharma S, Hullatti KK, Kumar S. Comparative antioxidant activity of *Cuscuta Reflexa* and *Cassytha filiformis*. *Journal of Pharmacy Research*. 2012;5:441-443.
- Pandit S, Chauhan NS, Dixit VK. Effect of *Cuscuta Reflexa* Roxb on androgen-induced alopecia. *Journal of Cosmetic Dermatology*. 2008;7(3):199-204.
- Patel S, Sharma V, Chauhan NS, Dixit VK. An updated review on the parasitic herb of *Cuscuta Reflexa* Roxb. *Journal of Chinese Integrative Medicine*. 2012;10(3):249-255.
- Sofowora A. Screening plants for bioactive agents. In: *Medicinal Plants and Traditional Medicine in Africa*. 2nd ed., Spectrum Books Ltd., Ibadan, Nigeria; c1993, p134-156.
- Trease GE, Evans WC. *Pharmacognosy*. 15th ed., Saunders Publishers, London, c2002, 42-393.
- Ecobichon DJ. *The basis of toxicology testing*. New York: CRC Press, c1997, 43-86.
- King J. The transferases-alanine and aspartate transaminases. In: Van D, editor. *Practical Clinical Enzymology*. London: Nostrand Company Ltd; c1965; 191-208.
- King J. The hydrolases-acid and alkaline phosphatases. In: Van D, editor. *Practical Clinical Enzymology*. London: Nostrand Company Ltd, c1965; 191-208.
- Lowry OH, Rosenbrough NJ, Farr AL, Randall RJ. Protein measurement with the Folin phenol reagent. *Journal of Biological Chemistry*. 1951;193(1):265-75.
- Malloy HT, Evelyn KA. Determination of bilirubin. *Journal of Biological Chemistry*. 1937;119:481-490.
- Suja SR, Latha PG, Pushpangadan P, Rajasekaran S. Evaluation of hepatoprotective effects of *Helminthostachys zeylanica* (L) Hook against carbon tetrachloride induced liver damage in Wistar rats. *Journal of Ethnopharmacology*. 2004;92(1):61-66.
- Yadav NP, Dixit VK. Hepatoprotective activity of leaves of *Kalanchoe pinnata* Pers. *Journal of Ethnopharmacology*. 2003;86(2-3):197-202.
- Achliya GS, Wadodkar SG, Dorle AK. Evaluation of hepatoprotective effect of Amalkadi Ghrita against carbon tetrachloride induced hepatic damage in rats. *Journal of Ethnopharmacology*. 2004;90(2-3):229-232.
- Shenoy AK, Somayaji SN, Bairy KL. Evaluation of hepatoprotective activity of Ginkgo biloba in rats. *Indian Journal of Pharmacology*. 2002;46(2):167-174.
- Bhandarkar MR, Khan A. Antihepatotoxic effect of *Nymphaea stellata* Willd against carbon tetrachloride induced hepatic damage in albino rats. *Journal of Ethnopharmacology*. 2004;91:61-64.
- Decker K, Keppler D. Galactosamine-induced liver injury. In: Popper H, Schaffner F, editors. *Progress in Liver Disease*. New York: Grune, Stratton; c1972, 183-99.
- Srivastava S, Nighojkar A, Kumar A. Multiple forms of pectin methylesterase from *Cuscuta Reflexa* filaments. *Phytochemistry*. 1994;37(5):1233-1236.
- Yadav SB, Tripathi V, Singh RK, Pandey HP. Flavonoid glycosides from *Cuscuta Reflexa* stems and their antioxidant activity. *Indian Drugs*. 2001;38(2):95-96.